

A BLOOD-SUCKING SPECIES OF PERICOMA IN QUEENSLAND (DIPT.).

By FRANK H. TAYLOR, F.E.S.,

The Australian Institute of Tropical Medicine.

(PLATE VII.)

Hitherto no flies of the family PSYCHODIDAE have been recorded from Australia. However, during the year 1913 three specimens of a single species were taken in Townsville, one of which was subsequently submitted to Mr. E. E. Austen, who informed the author that it belonged to the genus *Pericoma* and was probably a new species. As I have been unable to determine it as one of Brunetti's Oriental species, I now describe it as new.

I wish to acknowledge with gratitude Mr. Austen's generous assistance to me on this and many other occasions.

***Pericoma townsvillensis*, sp. n.**

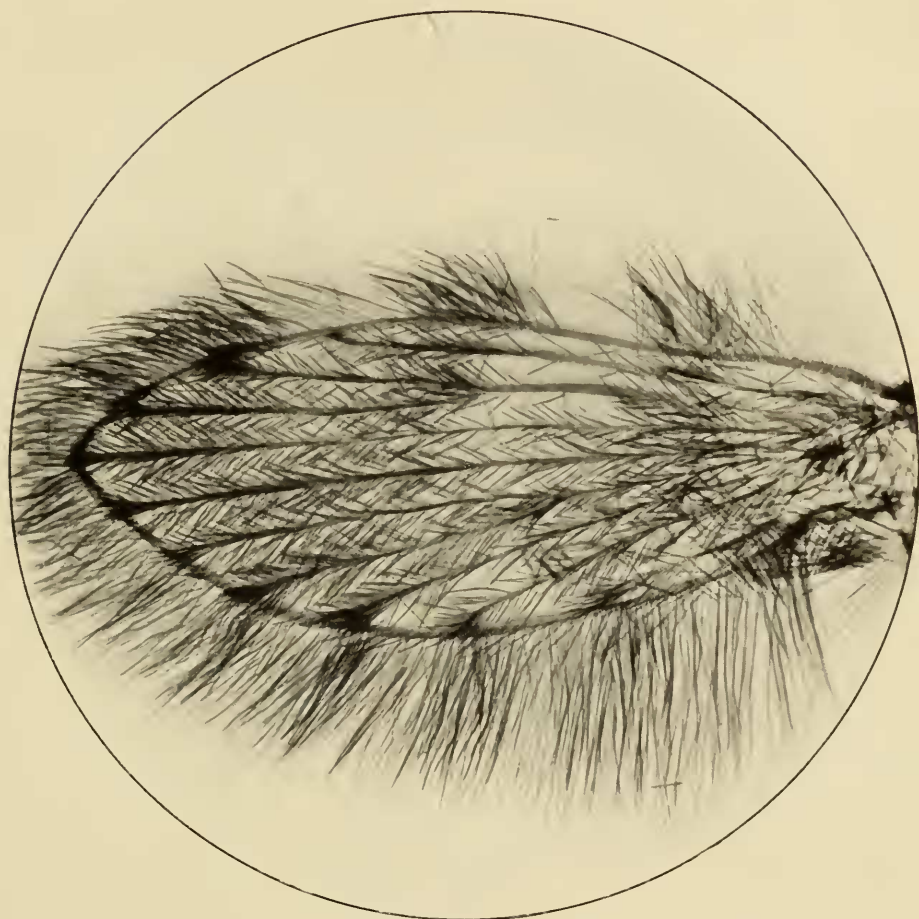
Head densely clothed with brown hairs with white apices; antennae pale, with white verticillate hairs, the base and second segment clothed with pale scales; palpi densely clothed with black scales. *Thorax* clothed with light brown hairs with white tips. *Abdomen* with very dense brown hairs with snow-white tips; venter clothed with dark brown hairs. *Legs* pale, covered with dark scales; the apex of the first tarsals white, all remaining tarsi white; the femora, tibiae and first tarsals with dark hairs and bristles, which are particularly prominent on the first tarsals and hind tibiae. *Wings* densely clothed with dusky hairs; fringe dusky and very prominent; veins pale, their apices and the forks of the second and fourth veins with very distinct black, scaly hair-spots.

Length, 1.7 mm.

QUEENSLAND: Townsville (*Dr. H. Priestley* and *F. H. Taylor*).

Described from two specimens (a third in the British Museum), which were captured indoors during May. This species is a very severe biter, the irritation remaining for some hours. In one case the swelling raised by the bite was surrounded by a marked reddish areola, both of which persisted for three weeks.

Type and one other specimen in the collection of the Institute.



Wing of *Pericoma townsvillensis*, Taylor, sp.n.